




# #DIBS BY NEXTILLO

DAILY INFORMATION BULLETIN SERVICE

PHARYNX





# #DIBSBYNEXTILLO

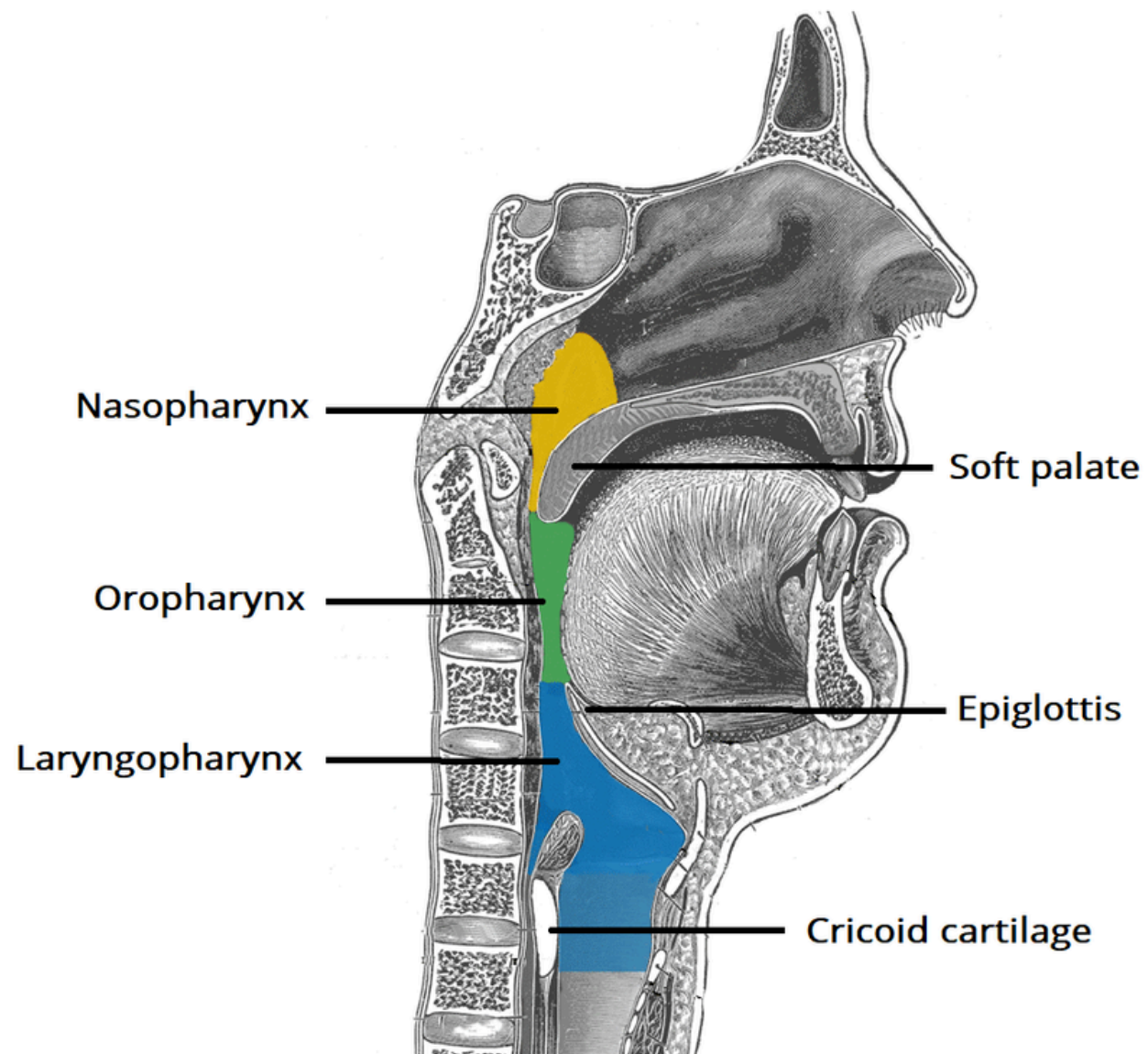
*DAILY INFORMATION BULLETIN SERVICE*

## PHARYNX

The pharynx is a hollow, muscular tube inside the neck that starts behind the nose and opens into the larynx and esophagus. The three parts of the pharynx are the nasopharynx, oropharynx, and hypopharynx.



# VISUAL REPRESENTATION





# NASOPHARYNX

- **Location:** Extending from the skull base (C1) to the palate.
- **Structures:** Surrounded by adenoids, Eustachian tube, Torus tubaris, Fossa of
- **Key Points:** Acts as a gateway for both air and food passages.
- **Clinical Relevance:** Crucial for diagnosing conditions affecting the upper throat, such as adenoid issues.
- **Eustachian Tube Connection:** The nasopharynx connects with the middle ear through the Eustachian tube, and affects the middle ear ventilation and pressure regulation.



# OROPHARYNX

- **Location:** Situated between cervical vertebrae C1 to C3, spanning from the palate to the hyoid.
- **Structures:** Enriched with anatomical elements like the base of the tongue, Pillars, Tonsils, and the Posterior Pharyngeal Wall (PPW).
- **Significant Point:** Hosts the tonsils, critical for immune defense in the upper throat.
- **Clinical Significance:** Frequent site for infections, and understanding its anatomy is vital for surgical procedures.
- **Speech and Swallowing Coordination:** The oropharynx is integral in coordinating movements required for both speech and swallowing.



# CLINICAL CONSIDERATIONS

- **Location:** *Positioned between cervical vertebrae C3 to C6, extending from the hyoid to the cricoid.*
- **Structures:** *Envelops significant features like the Pyriform sinus, Post-cricoid region, and the Posterior Pharyngeal Wall (PPW).*
- **Significant:** *Spans the anatomical region between cervical vertebrae C3-C6.*
- **Clinical Implications:** *Key for managing conditions affecting the lower throat, including cancers involving the hypopharynx.*



# MCQ

***Which part of the pharynx is located between the base of the skull and the soft palate?***

- A. Oropharynx***
- B. Laryngopharynx***
- C. Nasopharynx***
- D. Hypopharynx***

***Answer: C. Nasopharynx***

