




#DIBS BY NEXTILLO

DAILY INFORMATION BULLETIN SERVICE

VARIOUS SPACES IN HAND





#DIBSBYNEXTILLO

DAILY INFORMATION BULLETIN SERVICE

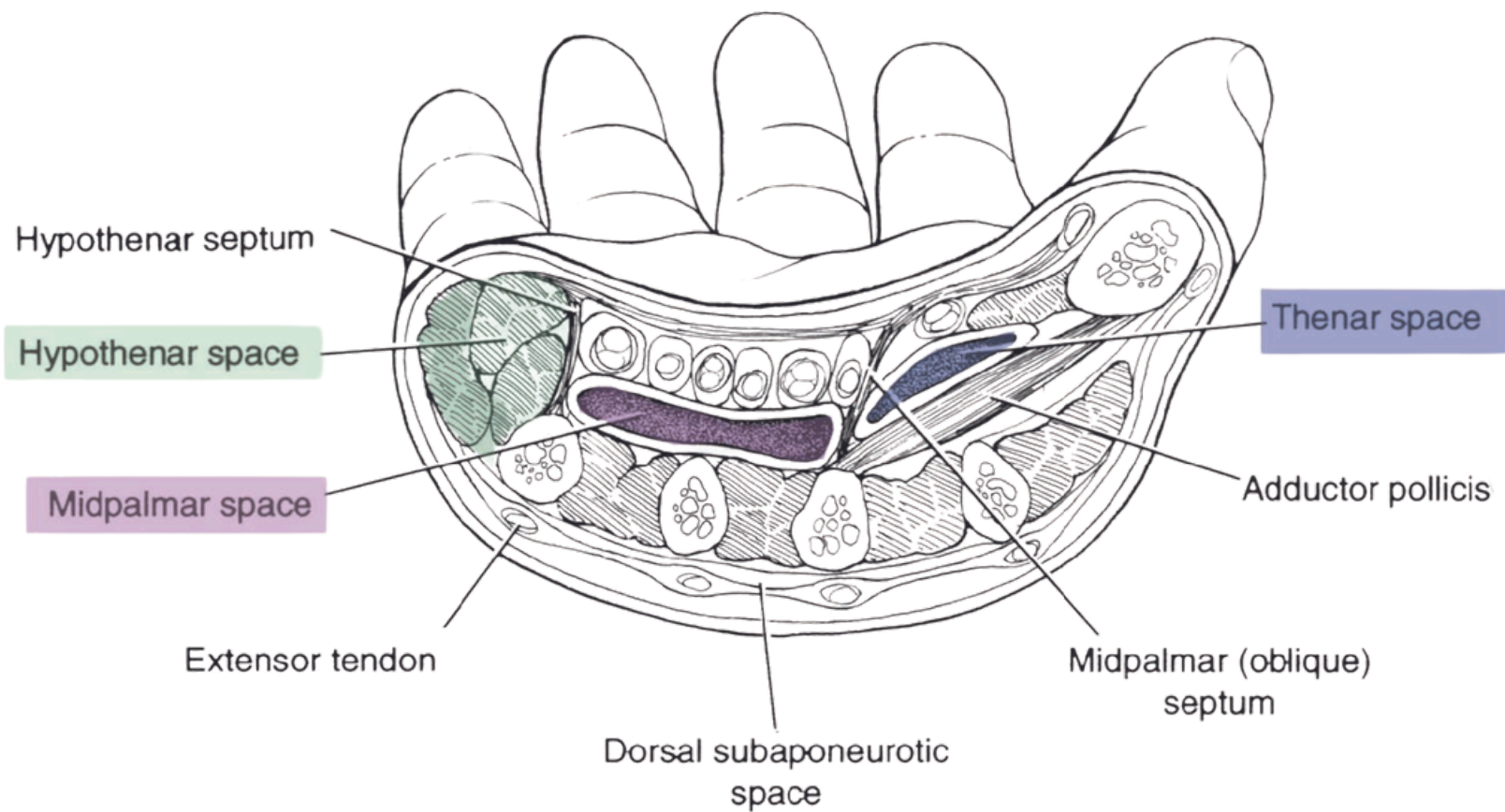
VARIOUS SPACES IN HAND

There are two varieties of hand spaces:

- (1) potential anatomical spaces that are bordered within muscle planes or by fascial bands and
- (2) true anatomical spaces that are lined by synovial membrane.



VISUAL REPRESENTATION





VARIOUS SPACES IN HAND

HAND SPACES

- *Lateral Half of Palm:*
 - - *FDI located in the hollow of palm.*
 - - *Limited proximally by carpal tunnel walls.*
 - - *Distally communicates with the 1st web space.*
- *Thenar Space.*
 - - *Contains FPL and index finger flexor tendons.*
 - - *Communicates distally with the 1st web space.*
 - - *Drainage via incision in thumb web space.*



VARIOUS SPACES IN HAND

- *Midpalmar Space:*
 - - *Under the medial half of the palm.*
 - - *Houses flexor tendons of medial 3 digits.*
 - - *Continuous with forearm space of Parona.*
- *Ulnar Bursa:*
 - - *Envelops FDS, FDP tendons with common sheath.*
 - - *Proximally extends 2.5cm beyond flexor retinaculum.*
 - - *Drainage through radial margin of hypothenar eminence.*
- *Radial Bursa:*
 - - *Synovial sheath for FPL.*
 - - *Extends 2.5cm beyond flexor retinaculum.*
 - - *Drainage at medial margin of thenar eminence.*



VARIOUS SPACES IN HAND

CLINICAL IMPLICATIONS

- *Infections in Hand Spaces:*
 - - *Radial bursa and thenar space: risk from synovial sheaths.*
 - - *Ulnar bursa infections may affect medial 2 web spaces.*
- *Drainage Procedures:*
 - - *Thumb web space for thenar space infections.*
 - - *Radial margin of hypothenar eminence for ulnar bursa.*
- *Communications and Continuities:*
 - - *Interconnected spaces via lumbricals and web spaces.*
 - - *Proximal continuity between midpalmar and forearm spaces.*
- *Specific Tendon Involvement:*
 - - *Ulnar bursa covers FDS, FDP tendons.*
 - - *Radial bursa specific to FPL tendon.*



MCQ

Question: What hand space is vulnerable to infections originating from the radial bursa or synovial sheath?

- (A) Midpalmar space**
- (B) Ulnar bursa**
- (C) Thenar space**
- (D) Forearm space of Parona**

Answer: (C) Thenar space