


#DIBS BY NEXTILLO

DAILY INFORMATION BULLETIN SERVICE

ANNULAR PANCREAS





#DIBSBYNEXTILLO

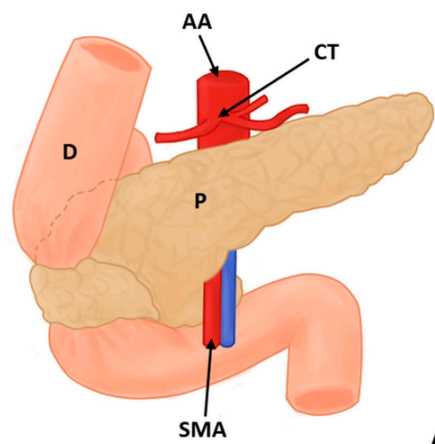
DAILY INFORMATION BULLETIN SERVICE

ANNULAR PANCREAS

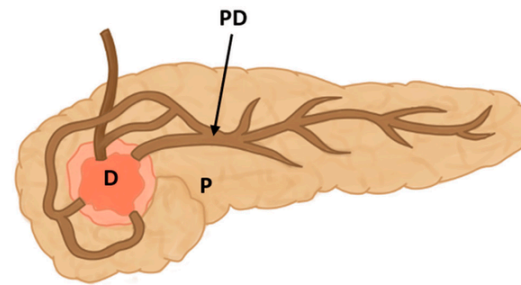
Annular pancreas is a congenital anomaly where a ring of pancreatic tissue surrounds the second part of the duodenum, the initial segment of the small intestine. This anomaly results from improper rotation of the pancreatic buds during embryonic development.



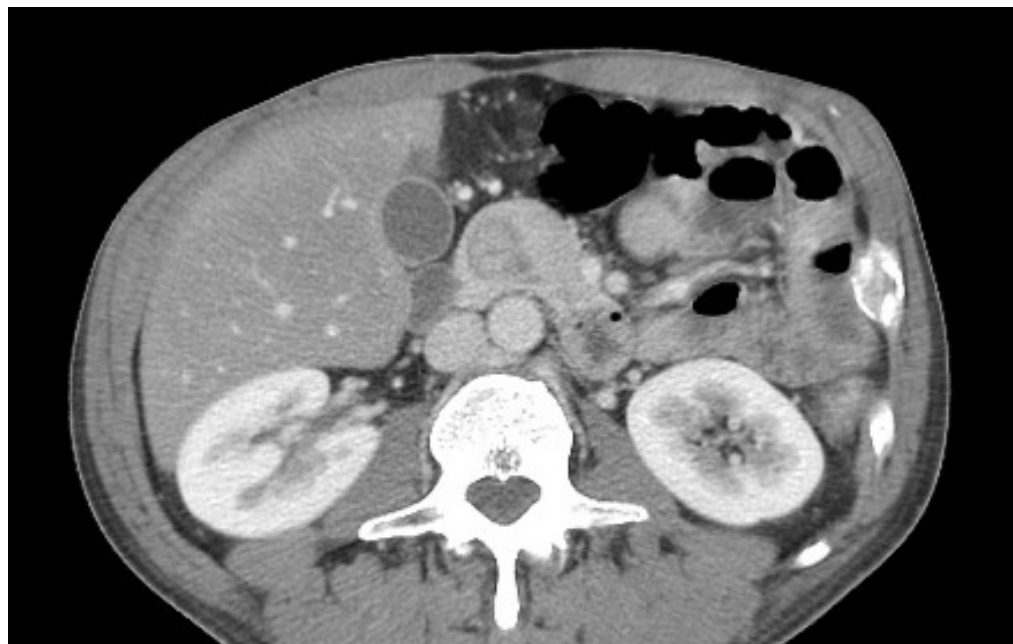VISUAL REPRESENTATION



A



B





PANCREAS DIVISUM

- **Ring of ventral pancreas around 2nd part of duodenum.**
- **Located proximal to ampulla**
- **Associated with *Down's syndrome and duodenal atresia.***

Clinical Features:

- **Non bilious vomiting because obstruction is proximal to ampulla.**

Investigations:

- **IOC: ERCP**

Management:

- **TOC: Duodeno-duodenostomy > Duodeno-jejunostomy**



MCQ

Question: What is the primary treatment for annular pancreas?

- A) Antibiotics***
- B) Lifestyle modifications***
- C) Surgical intervention***
- D) Radiation therapy***

Answer: C) Surgical intervention