


#DIBS BY NEXTILLO

DAILY INFORMATION BULLETIN SERVICE

PARTS OF PHARYNX





#DIBSBYNEXTILLO

DAILY INFORMATION BULLETIN SERVICE

PARTS OF PHARYNX

The pharynx is a hollow, muscular tube inside the neck that starts behind the nose and opens into the larynx and esophagus.

The three parts of the pharynx are the nasopharynx, oropharynx, and hypopharynx.



MAIN DIVISIONS OF PHARYNX

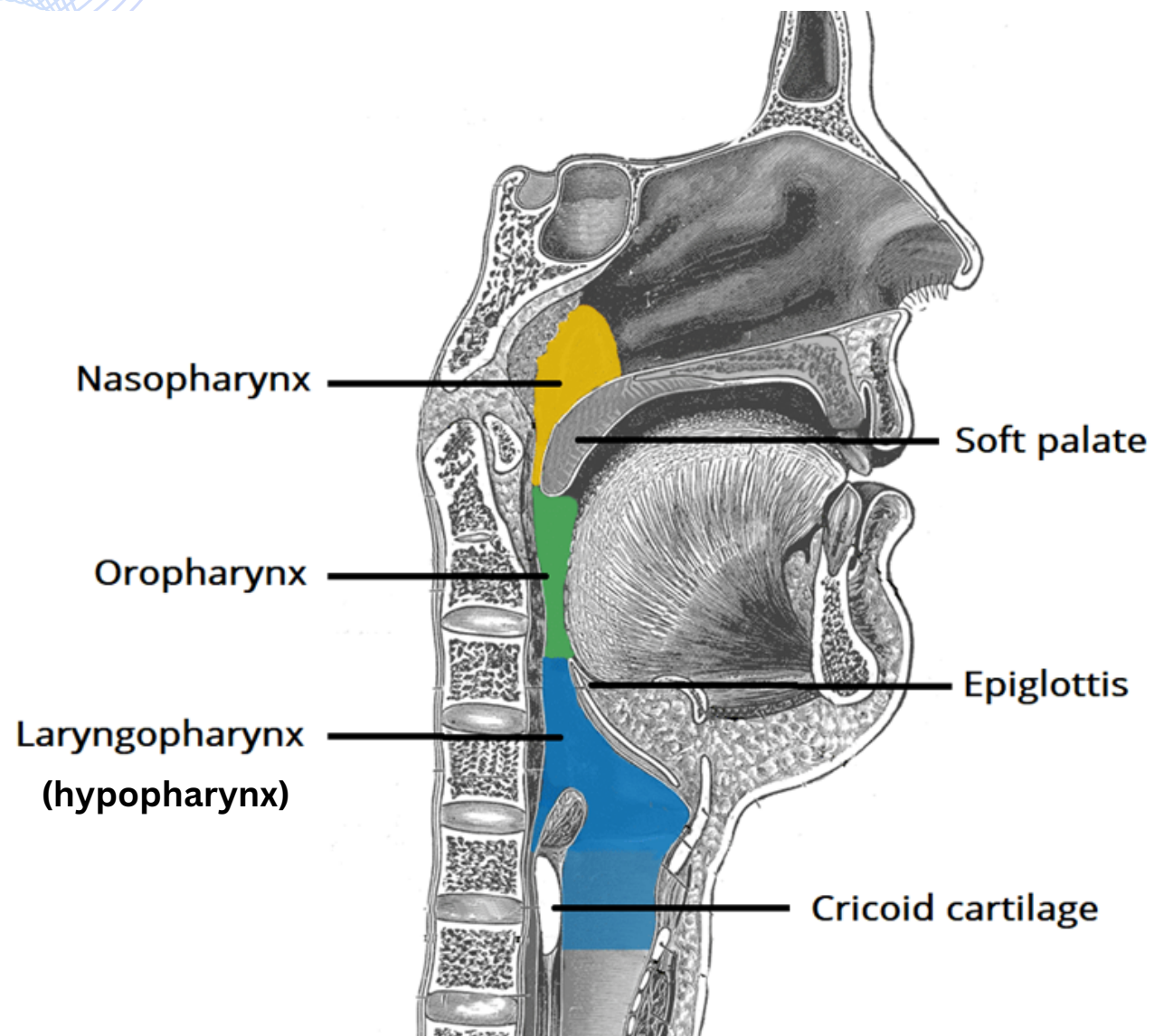
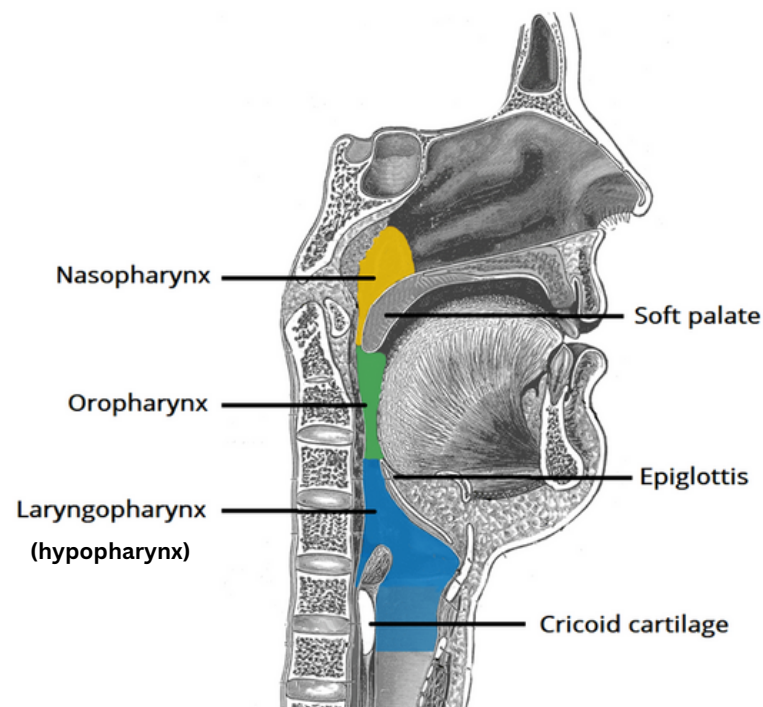




IMAGE DESCRIPTION



- *The image illustrates the three main divisions of the pharynx: nasopharynx, oropharynx, and hypopharynx.*
- *Nasopharynx contains adenoids, pharyngeal constrictor muscles, levator palatini muscle and torus tubarius.*
- *Oropharynx involves tongue, palatine tonsils, and superior constrictor muscle.*
- *Laryngopharynx contains middle and inferior pharyngeal constrictors.*



NASOPHARYNX

Location:

Extending from the skull base (C1) to the palate.

Structures:

Surrounded by adenoids, Eustachian tube, Torus tubaris, Fossa of Rossenmuller.

Key Points:

Acts as a gateway for both air and food passages.

Clinical Relevance:

Crucial for diagnosing conditions affecting the upper throat, such as adenoid issues.



OROPHARYNX

Location:

Situated between cervical vertebrae C1 to C3, spanning from the palate to the hyoid.

Structures:

Enriched with anatomical elements like the base of the tongue, Pillars, Tonsils, and the Posterior Pharyngeal Wall (PPW).

Significant Point:

Hosts the tonsils, critical for immune defense in the upper throat.

Clinical Significance:

Frequent site for infections, and understanding its anatomy is vital for surgical procedures.



HYPOPHARYNX

Location:

Positioned between cervical vertebrae C3 to C6, extending from the hyoid to the cricoid.

Structures:

Envelops significant features like the Pyriform sinus, Post-cricoid region, and the Posterior Pharyngeal Wall (PPW).

Significant:

Spans the anatomical region between cervical vertebrae C3-C6.

Clinical Implications:

Key for managing conditions affecting the lower throat, including cancers involving the hypopharynx.



PARTS OF PHARYNX

Question:

Which part of the pharynx is located between the base of the skull and the soft palate?

- A.) Oropharynx
- B.) Laryngopharynx
- C.) Nasopharynx
- D.) Hypopharynx

Answer: C.) Nasopharynx